

# Non-Specific Granulomatous Prostatitis: A Diagnosis of Exclusion

V.S. KUNDARGI, NILESH GURU, S.B. PATIL, B.S. PATIL, KSHITIZ RANKA

## ABSTRACT

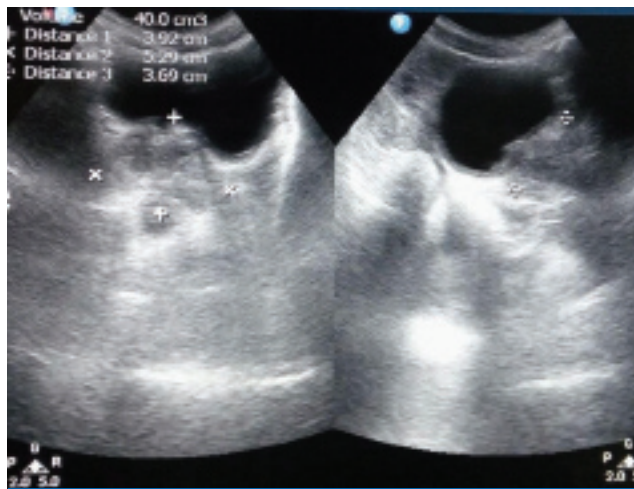
Granulomatous prostatitis is a rare inflammatory condition of prostate. The diagnosis of this entity continues to remain a clinical surprise for the treating urologist. They represent a clinical diagnostic dilemma as some of the cases mimic malignancy. The radiological findings and serum prostate specific antigen levels are non-specific in their diagnosis. The definitive diagnosis can be established only by histopathological examination. It is essential to

typify the granulomatous prostatitis histologically, so as to guide the management. The presence of Langhans type and foreign body type giant cells with the presence of necrosis does not confirm the diagnosis of tubercular prostatitis, confirmation in fact requires Ziehl-Neelsen staining and tubercular polymerase chain reaction. Non-specific granulomatous prostatitis represents the majority of the cases of granulomatous prostatitis.

**Keywords:** Granuloma, Tubercular polymerase chain reaction, Ziehl-Neelsen staining

## CASE REPORT

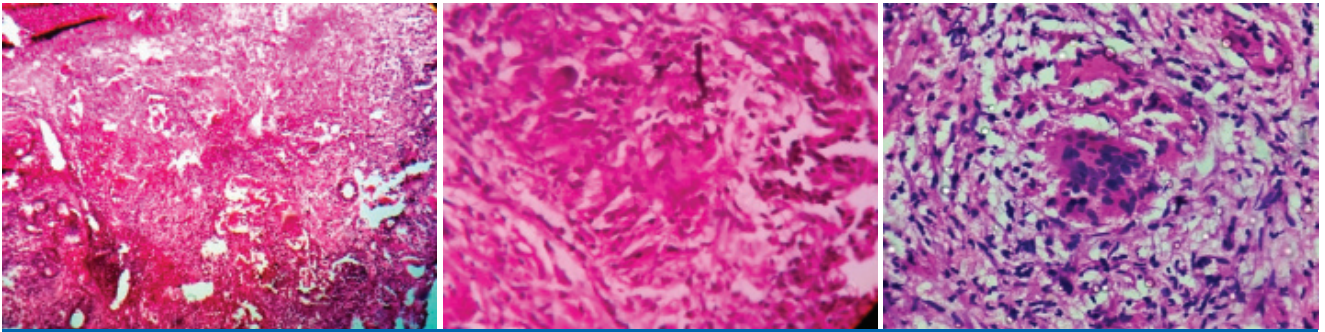
A 60-year-old male patient presented to Urology Department with six months history of increased frequency of micturition, nocturia, difficulty in micturition and hesitancy. Patient had no history of pulmonary or extrapulmonary tuberculosis. On digital rectal examination, prostate was firm in consistency. His American Urological Association (AUA) symptom score was 24 (severe symptoms). Urine Analysis was within normal limits. Ultrasonography abdomen and pelvis done suggested 40(5x4x4)gm of prostate [Table/Fig-1] with 190 mL post



[Table/Fig-1]: Ultrasonography KUB s/o prostatomegaly.

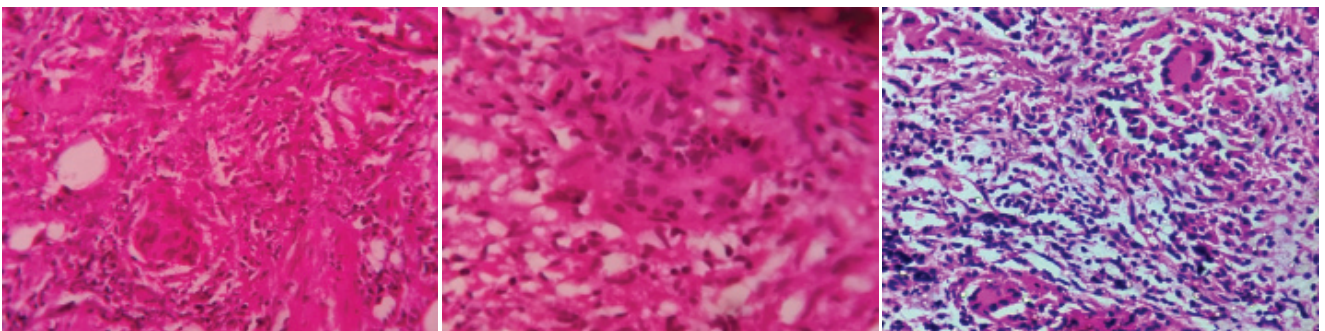
void residue and normal upper urinary tract. Serum Prostate Specific Antigen (PSA) levels were 1.0 ng/l. His renal function tests and complete blood counts were within normal limits. His chest x-ray PA view, plain x-ray Kidney Ureter Bladder (KUB) was normal. Urine flow rate at uroflowmetry was 8 mL/sec at 170 mL voided volume. In view of obstructive symptoms, patient was taken up for transurethral resection of prostate with informed consent. Prostate was firm on resection, prostatic urethra congested and bladder on cystoscopy showed trabeculations. Resection was complete with roomy prostatic fossa and the prostatic chips were whitish. The histopathological examination revealed ill formed granulomas in the fibromuscular stroma, comprising of multinucleated giant cells of both Langhans and foreign body type, lymphocytes, fibroblasts, with central areas of necrosis, negative for Ziehl Neelsen staining for AFB [Table/Fig-2-7]. Tissue sent for Tubercular- Polymerase Chain Reaction (TB-PCR) and result was negative.

Based on the history, clinical examination and investigations our differential diagnosis was prostatomegaly due to benign prostatic hyperplasia and chronic prostatitis. Based on histopathological picture, our diagnosis was granulomatous prostatitis. However, based on Ziehl Neelsen staining and TB-PCR our final diagnosis was idiopathic non-specific granulomatous prostatitis. In the follow-up period of six months, patient was symptom-free and voiding well.



**[Table/Fig-2]:** Granulomatous prostatitis with lymphocytic infiltration and granulomas seen on the luminal side of the prostatic tissue.

**[Table/Fig-3]:** Showing lymphocytic infiltration and multinucleated giant cells. **[Table/Fig-4]:** Granulomatous prostatitis with granuloma formation. (Images from left to right)



**[Table/Fig-5]:** Granuloma formation. **[Table/Fig-6]:** Granulomas with epithelioid cells. **[Table/Fig-7]:** Granulomatous prostatitis with dense lymphocytic infiltration and multinucleated giant cells. (Images from left to right)

## DISCUSSION

Tanner and McDonald described granulomatous prostatitis as a rare and unusual inflammatory condition of prostate [1]; that histologically features the presence of granulomas. Literature has description of a variety of granulomatous lesions of prostate with varied etiology and pathogenesis. The relevance of prompt diagnosis of these lesions lies in the fact that few of these lesions e.g., non-specific granulomatous prostatitis mimic prostatic carcinoma on clinical examination and serum Prostate Specific Antigen (PSA) levels. We here present a case report of non-specific granulomatous prostatitis diagnosed on histopathological examination after ruling out tubercular granulomatous prostatitis by ZN staining and tubercular-PCR.

Granulomatous prostatitis is a rare inflammatory condition of prostate with a reported incidence of 3.3% [1]. H Mohan et al., showed 1.5% incidence of granulomatous prostatitis [2]. Kumbar et al., [1] reported an incidence of 1.4%

Diagnosis of non-specific granulomatous prostatitis is mostly incidental detected histologically in examined prostatic specimen retrieved by needle biopsy, simple prostatectomy or TURP [3,4].

Amongst the patients receiving intravesical BCG treatment, 1.3% are affected by tubercular prostatitis [5]. Prostate is

affected in systemic tuberculosis in 3%-12% of patients. There is co-existing pulmonary tuberculosis in >90% of cases of tubercular prostatitis. 75-95% of cases of genitourinary tuberculosis show tubercular prostatitis [6].

Carcinoma prostate can coexist with granulomatous prostatitis in 10-14% of cases [4,6].

Common symptoms include irritative and obstructive voiding symptoms, fever and chills. In a study conducted by Kumbar et al., [1], 17 patients with granulomatous prostatitis aged between 51-75 years with the most common presenting symptom being increased frequency with/without obstruction. Digital rectal examination was suggestive of firm and nodular mass in 6 and hard fixed nodule in 11 cases. The PSA levels in their study ranged from 2.8 ng/mL to 28.8 ng/mL with mean PSA levels being 15.8 ng/mL.

Granulomatous Prostatitis is classified by Young HR et al., [7] as idiopathic, iatrogenic, infectious, systemic and malakoplakia. The idiopathic category includes non-specific granulomatous prostatitis and xanthogranulomatous prostatitis. Our case falls into category of idiopathic non specific granulomatous prostatitis.

In a study conducted by Kumbar et al., [1] non-specific granulomatous prostatitis accounted for 53% of cases, xanthogranulomatous prostatitis was seen in 29.4% of cases

and tubercular prostatitis in 17.6% of cases

Idiopathic granulomatous prostatitis accounts for the majority of the cases. It is hypothesised that it occurs secondary to foreign body response to the refluxed urine, products of microbes; or body's immunological response to the extra prostatic secretions [2,8].

Early lesions of tubercular granulomatous prostatitis are rarely detected on palpation as these are associated with caseation, cavitation and sinus tracts into rectum, perineum or the peritoneal cavity [1]. However, the late stages are marked by shrunken and fibrotic gland mimicking clinically to carcinoma.

After the offending agents incites the event, there is dilatation of ducts and acini and are filled with neutrophils, foamy histiocytes, and desquamated epithelial cells, which is followed by the rupture of the ducts and acini and recruitment of lymphocytes, plasma cells, histiocytes, and multinucleated giant cells establishing granulomatous inflammatory reaction. These dense nodules of inflammatory infiltrate obscure and efface ductal and acinar elements [4].

Nikhil et al.,[9] presented a case report of histologically diagnosed xanthogranulomatous prostatitis in which there was no clinical suspicion and resection revealed yellowish chips of prostate which subsequently turned out to be xanthogranulomatous prostatitis. Xanthogranulomatous prostatitis is confused with clear cell prostatic carcinoma histopathologically. On microscopic examination one can see foamy macrophages with dark eccentric nuclei or localised collection of cholesterol laden histiocytes and is often seen as a solitary lesion in the peripheral zone or transition zone [10]. Histopathological examination of the resected prostatic tissue remains the gold standard for diagnosing granulomatous prostatitis [1].

Infectious granulomatous prostatitis can be confirmed by using various stains like haematoxylin and eosin stain, Gomori's stain, ZN stain and Periodic Acid Schiff (PAS) stain [1]. Granulomatous prostatitis are histologically characterised by dense lymphocytic infiltration, presence of granulomas and giant cells. Histologically cases of non-specific granulomatous prostatitis shows the presence of granulomas consisting of histiocytes, epitheloid cells, lymphocytes, and foreign body type giant cells [1], while cases of xanthogranulomatous prostatitis shows the typical presence of foamy macrophages or the xanthoma cells [9] in addition to the other cells; and lastly tubercular granulomatous prostatitis is characterised by the presence of Langhans type of giant cells with focal areas of necrosis [1]. However, confirmation of tubercular granulomatous prostatitis requires ZN staining and TB-PCR on the resected prostatic specimen.

Kawada H et al.,[11] in his study demonstrated features in

the multiphase contrast-enhanced MR imaging used to differentiate between BCG-induced granulomatous prostatitis and carcinoma prostate. In a study performed in five patients he found that all BCG- induced lesions had lower signal intensity compared with that in the normal peripheral zone on T2-weighted images (T2WIs), and higher signal intensity on T1-weighted images (T1WIs), while Diffusion Weighted Images (DWIs) showed high signal intensity and low Apparent Diffusion Coefficient (ADC) values. Kawada H et al., [11] pointed out that BCG-induced granulomatous prostatitis lesions showed early and prolonged ring enhancement on Gadolinium-enhanced multiphase MR imaging, while carcinoma prostate shows early enhancement and rapid contrast washout due to increased vascularity. Adding more they found that BCG induced granulomatous lesions in prostate showed decrease in size over time with anti-tubercular treatment which could also help in differentiating them from carcinoma prostate.

The detection of subtype of granulomatous prostatitis by histological evaluation is the key to guide the treatment as management differs with the subtype [1].

Kumbar et al.,[1] found that all nine cases of non-specific granulomatous prostatitis were self limiting and had uneventful follow-up period. He started with anti-tuberculous therapy comprising of triple drug regimen of rifampicin, ethambutol and isoniazid for six months in all three cases of tubercular prostatitis. Most cases of iatrogenic granulomatous prostatitis resolve spontaneously [12].

It is opined that if needle biopsy confirms the diagnosis of granulomatous prostatitis, it is prudent to avoid surgical intervention as it carries the risk of bladder neck contracture and the need of repeated resection [2].

## CONCLUSION

Granulomatous prostatitis continues to be a histological surprise for the treating urologist. It is very difficult to anticipate this entity on clinical evaluation and there are no specific radiological features. The importance of diagnosing granulomatous prostatitis lies in the fact that some of the cases clinically mimic malignancy and the knowledge of the subtype of granulomatous prostatitis helps us to guide the treatment accordingly. The presence of Langhans type and foreign body type giant cells with the presence of necrosis does not confirm the diagnosis of tubercular prostatitis, confirmation in fact requires ZN staining and tubercular polymerase chain reaction. It is necessary to document and report more and more cases of granulomatous prostatitis to aid to our diagnostic knowledge.

## REFERENCES

- [1] Kumbar R, Dravid N, Nikumbh D, Patil A, Nagappa KG. Clinicopathological overview of granulomatous prostatitis: an appraisal. *J Clin Diagn Res.* 2016;10(1):EC20-23.

- [2] Mohan H, Bal A, Punia RPS, Bawa AS. Granulomatous prostatitis – an infrequent diagnosis. *International Journal of Urology*. 2005;12:474–78.
- [3] Val-Bernal JF, Zaldumbide L, Garijo FM, Gonzalez-Vela MC. Nonspecific (idiopathic) granulomatous prostatitis associated with low grade prostatic adenocarcinoma. *Ann Diagn Pathol*. 2004;8:242–46.
- [4] Epstein IJ, Yang JX. 3<sup>rd</sup> ed. Philadelphia: Lippincott W&W; 2002. Inflammatory conditions. In: Prostate biopsy interpretation; pp. 19–32.
- [5] Leibovici D, Zisman A, Chen-Levy Z, et al. Elevated prostatic specific antigen serum levels after intravesicle instillation of bacille Calmette-Guerin. *J Urol*. 2000;164:1546–49.
- [6] Shanggar K, Zulkifli MZ, Razack AH, Dublin N. Granulomatous prostatitis: A remainder to clinicians. *Med J Malaysia*. 2010;65(1):21–22.
- [7] Young HR, Srigley RJ, Amin BM, Ulbright MT, Cubilla LA. Tumour – like lesions of the prostate. In: Tumours of the prostate gland, seminal vesicles, male urethra and penis: Atlas of Tumour pathology. Washington DC: Armed Forces Institute of Pathology (AFIP-28); 1998. pp. 289–345.
- [8] Oppenheimer JR, Kahane H, Epstein JI. Granulomatous prostatitis on needle biopsy. *Arch Pathol Lab Med*. 1997;121:724–29.
- [9] Patil N, Kundargi VS, Patil SB, Biradar AK, Desai AS. Xanthogranulomatous prostatitis: a rare case report. *Med Surg Urol*. 2014;3:131.
- [10] Sebo JT, Bostwick GD, Farrow MG, Eble NJ. Prostatic xanthoma: A mimic of prostatic adenocarcinoma. *Hum Pathol*. 1994;25(4):386–89.
- [11] Kawada H, Kanematsu M, Goshima S, et al. Multiphase contrast-enhanced magnetic resonance imaging features of bacillus Calmette-Guérin-induced granulomatous prostatitis in five patients. *Korean Journal of Radiology*. 2015;16(2):342–48.
- [12] Shruti D, Sabiha M, Sadhana M, Pragati K. non-specific granulomatous prostatitis –masquerading carcinoma prostate. *IOSR Journal of Dental and Medical Sciences*. 2015;14(8):28–30.

**AUTHOR(S):**

1. Dr. V.S Kundargi
2. Dr. Nilesh Guru
3. Dr. S.B Patil
4. Dr. B.S Patil
5. Dr. Kshitiz Ranka

**PARTICULARS OF CONTRIBUTORS:**

1. Professor, Department of Urology, Shri B.M. Patil Medical College and Hospital Research Centre, Bijapur, Karnataka, India.
2. Post Graduate Senior Resident, Department of Urology, Shri B.M. Patil Medical College and Hospital Research Centre, Bijapur, Karnataka, India.
3. Professor & HOD, Department of Urology, Shri B.M. Patil Medical College and Hospital Research Centre, Bijapur, Karnataka, India.

4. Assistant Professor, Department of Urology, Shri B.M. Patil Medical College and Hospital Research Centre, Bijapur, Karnataka, India.
5. Post Graduate Senior Resident, Department of Urology, Shri B.M. Patil Medical College and Hospital Research Centre, Bijapur, Karnataka, India.

**NAME, ADDRESS, E-MAIL ID OF THE CORRESPONDING AUTHOR:**

Dr. Nilesh Guru,  
Staff Quarters No.22, South A Block, Smt Bangaramma Sajjan Campus, Bijapur-586103, Karnataka, India.  
E-mail: nileshguru83@gmail.com

**FINANCIAL OR OTHER COMPETING INTERESTS:**

None.

Date of Publishing: Jan 01, 2017